

## CASE REPORT

## PEER REVIEWED | OPEN ACCESS

# Prosthetic rehabilitation using a cone morse dental implant and xenogen biomaterial in an aesthetic area: A case report

João Carlos Amorim Lopes, Saulo Henrique Salviano,  
Marco Antônio Carvalho, Jorge José de Carvalho, Renan Lana Devita,  
Pablo Dallario Ramalho Lucas, Igor da Silva Brum

## ABSTRACT

**Introduction:** With the worldwide growth of aesthetic treatments, oral rehabilitation has gained new vestments, where only the implant placement and their functional activation are not enough. It is necessary to do a whole three-dimensional planning, taking into account the remaining bone, possibilities of grafting before, during, or after the implant placement, the final prosthesis and especially the pink tissues handling and aesthetic. **Case Report:** In this case report, we can assess the loss of the dental element 22, which had a broad root lesion with almost total loss of the buccal wall. The extraction of this element was planned and a cone morse dental implant (Systhex® Avantt model, Curitiba, Brazil) was placed and grafted with a xenogenous biomaterial (Bio Oss®, Geistlich Pharm, Switzerland). After 9 months, it was reopened and the provisional prosthesis was made for tissue management. After this, a porcelain crown was cemented. **Conclusion:** We can conclude that when planning correctly and using a cone morse dental

implant, the prosthetic result and the surrounding soft tissues behave more favorably for an aesthetic format more compatible with current standards.

**Keywords:** Aesthetic, Biomaterial, Cone morse, Dental implants, Pink aesthetics

### How to cite this article

Lopes JCA, Salviano SH, Carvalho MA, de Carvalho JJ, Devita RL, Lucas PDR, Brum IDS. Prosthetic rehabilitation using a cone morse dental implant and xenogen biomaterial in an aesthetic area: A case report. J Case Rep Images Dent 2020;6: 100033Z07JL2020.

Article ID: 100033Z07JL2020

\*\*\*\*\*

doi: 10.5348/100033Z07JL2020CR

João Carlos Amorim Lopes<sup>1</sup>, Saulo Henrique Salviano<sup>2</sup>, Marco Antônio Carvalho<sup>3</sup>, Jorge José de Carvalho<sup>4</sup>, Renan Lana Devita<sup>5</sup>, Pablo Dallario Ramalho Lucas<sup>2</sup>, Igor da Silva Brum<sup>3</sup>

**Affiliations:** <sup>1</sup>Department of Implantology, Faculty of Dentistry, Portuguese Catholic University, Lisboa, Portugal; <sup>2</sup>Department of Implantology, Faculty of Dentistry, São Leopoldo Mandic University, Brasília, Brazil; <sup>3</sup>Department of Implantology, Faculty of Dentistry, State University of Rio de Janeiro, Rio de Janeiro, Brazil; <sup>4</sup>Department of Biology (IBRAG), Faculty of Medicine, State University of Rio de Janeiro, Rio de Janeiro, Brazil; <sup>5</sup>Department of Orthodontic, Faculty of Dentistry, State University of Barcelona, Barcelona, Spain.

**Corresponding Author:** Igor da Silva Brum, Department of Implantology, Faculty of Dentistry, State University of Rio de Janeiro, Rio de Janeiro, Brazil; Email: igor\_brum1@hotmail.com

Received: 11 May 2020  
Accepted: 01 July 2020  
Published: 20 July 2020

## INTRODUCTION

Oral rehabilitation of toothless spaces with osseointegrated dental implants has been a scientifically accepted and well-documented treatment modality for years. Since Branemark, in 1908, first discovered the concept of osseointegration, numerous investigations and clinical studies have established titanium as a reliable biomaterial for oral rehabilitation and reconstruction. Various modifications to the structure, composition, and design of titanium dental implants have been made to improve their physical, mechanical, and optical properties [1].

The ultimate goal of a dental implant is to restore missing or extracted teeth, loading anatomical and aesthetical restorations in the long term [2]. Preservation of the alveolar crest and management of the area after tooth extraction have a major impact on the volume of hard and soft tissues. The preservation of the socket

after extraction is sensitive to the technique, it is not 100% successful and sometimes unpredictable. Current techniques can delay the surgical placement of the implant for a few months, and the quality of new bone regeneration is questionable [3].

It is important to follow the clinical protocols for placing dental implants in aesthetic areas. Currently, the principle is the following: each case must be individually evaluated in order to achieve a satisfactory result: the balance of the three-dimensional bone and gingival architecture with the dental implant and prosthesis. Also there are other special recommendations for choosing the best moment for the placement of dental implants in aesthetic areas [4]. The precision in the implant position in aesthetic areas is more rigorous than in non-aesthetic areas. The good management of soft and hard tissues is the basis for an aesthetic result. Therefore, the implant placement in aesthetic areas must follow the exclusive principles and procedures of the region in question [5].

Although several studies have shown a survival rate above 95% of implants in the rehabilitation of the anterior maxilla in non-compromised patients and 97.9% in single teeth in the same area after eight years of follow-up, other authors mention a failure of 10% from the aesthetic point of view [6]. The dealing with aesthetic complications in implantology has been very well documented with scientific evidence, and some protocols have been created, which raises not only the success rate but the degree of aesthetic satisfaction [7].

Aesthetic results can be assessed objectively and subjectively. Subjective assessment can be performed using the patients' perception of the aesthetic result that can be measured using specific questionnaires in which patients can express their satisfaction or dissatisfaction [8]. The objective assessment can be performed by a professional examiner and is based on defined criteria, aiming at an overall assessment of the harmonic appearance and the natural integration of the artificial restoration with the patient's dentition. Both assessments must be taken into account to provide a complete overview of the final aesthetic result. So currently the evaluation protocols are taken into account when planning, because the level of satisfaction varies from patient to patient, which reduces this discrepancy between the perception of the dentist's vision and the patient's desire, obtaining a more favorable final result for both [9–11].

Data regarding the performance of the implant, including survival rates, success rates, and peri-implant bone loss are necessary to understand the advantages and disadvantages and their aesthetic enhancement [12, 13]. Although immediate implant placement is an attractive technique because it reduces the number of surgeries and increases patient satisfaction, it is still premature to conclude about its long-term results. Brum et al. [14]. claim that the use of biomaterials associated to dental implants bring excellent aesthetic results in relation to pink tissues, in addition to having perfect interaction with the grade IV titanium alloy [15].

The objective of the present study was to evaluate the gingival, bone, and prosthetic behavior in a case of a extraction of a dental element with periodontal lesion followed by immediate dental implant placement and biomaterial grafting. After a nine months healing period, the patient was rehabilitated with a ceramic crown.

## CASE REPORT

### Patient

This clinical case study followed the rehabilitation of a 31-year-old female patient, leukoderma, who needed oral rehabilitation using biomaterial and dental implants. The patient's main complaint was the pulsating pain she felt in the left lateral incisor in upper arch, which presented clinically gingival swelling and root exposure (Figure 1) and radiographically periapical lesion and partial loss of the buccal wall (Figure 2).

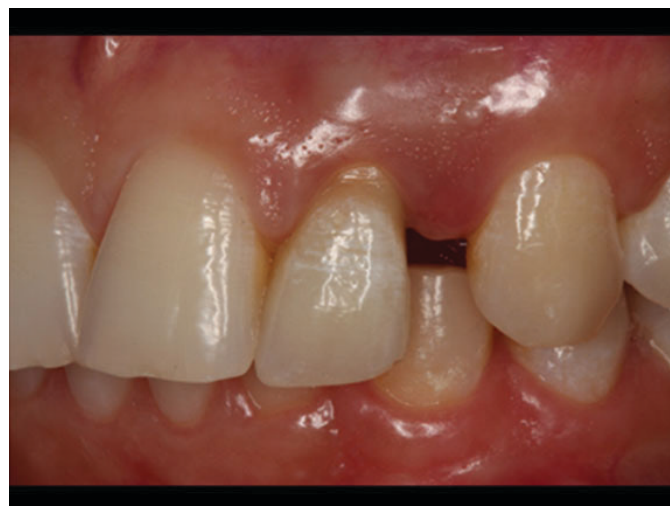

Figure 1: Initial photo.

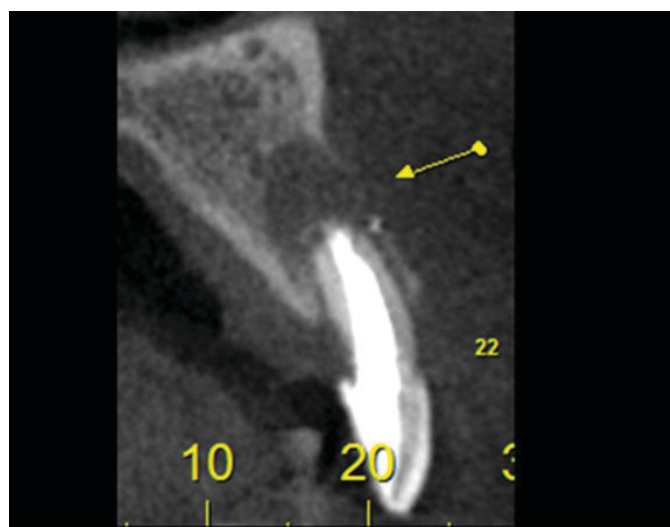


Figure 2: Initial radiographic view.



It was planned to perform the tooth extraction, implant placement, and biomaterial grafting at the same surgical moment followed by the placement of a provisional adhesive prosthesis fixed on adjacent teeth. Due to an increased mesiodistal space, orthodontic treatment was suggested in order to correct and adapt it to normal standards for the region. The follow-up time from the beginning to the end of the treatment was three years.

### Biomaterial and dental implant

In bone reconstruction surgery, xenogenous biomaterial Bio Oss® from the company Geistlich Pharm (Switzerland) was used. The implant used was a 3.5 × 13 mm cone Avantt model from Systhex® company (Curitiba, Brazil).

### Operative, postoperative and prosthetic management

The patient received antibiotics: 2 g of amoxicillin (4 × 500 mg capsules) 1 hour after surgery and Clavulin® 785 mg every 12 hours for 14 days. A rinse of 0.12% chlorhexidine solution for 1 minute was performed before the operation. Local anesthesia (2% lidocaine with adrenaline 1:100,000) was administered. Subsequently, an incision was made at the sulcular level and only one release incision positioned at the mesial buccal angle of the first upper left premolar. After this, a full thickness mucoperiosteal displacement was performed aiming a complete relaxation of the flap that was elevated to fully expose the alveolar bone, thus, the upper left lateral incisor was extracted, the endo-perio lesion was completely removed by curettage and the dental implant was placed (AvanttSysthex®, 3.5 × 13mm). All the pre-established concepts for immediate dental implant placement in alveolus were carried out, regarding: palatal approach and final positioning about two to four millimeters subcrestal. The next step was to carefully fill all “gaps” by the chosen biomaterial (Bio Oss® from Geistlich Pharm, Switzerland) and then protect with an absorbable membrane (Bio-Guide® from Geistlich Pharm, Switzerland) positioned over the entire length of the wound including the socket entrance. There was no sign of infection in the entire postoperative course (Figures 3–7).

After the reconstruction surgery, the patient underwent a new tomography where it was possible to observe the reconstruction of all previously lost alveolar structure (Figure 8).

After nine months, the reopening was performed followed by the provisional implant-supported placement in order to conditionate the gingival soft tissues (Figure 9). After the transfer and laboratory molding phase, the final ceramic crown was cemented (Figure 10). The final photo was obtained after one year of prosthetic function totaling three years of treatment.

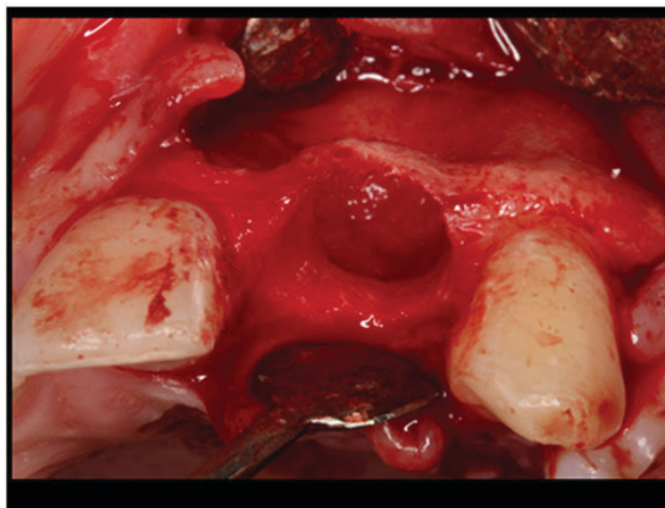


Figure 3: Extracted tooth and all inflammatory tissue removed.

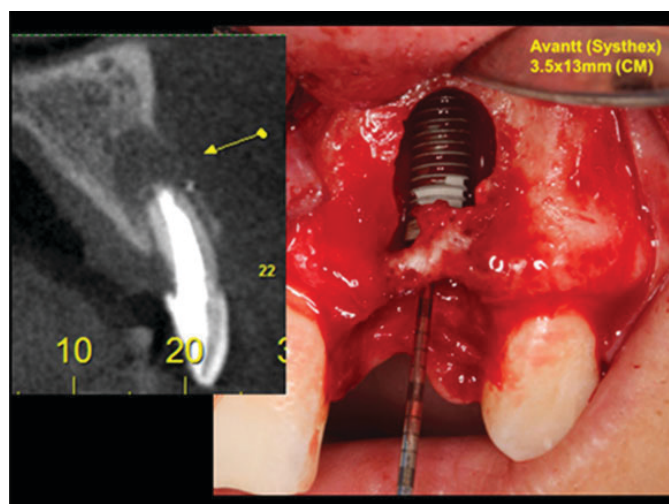


Figure 4: Subcrestal placement (buccal wall).

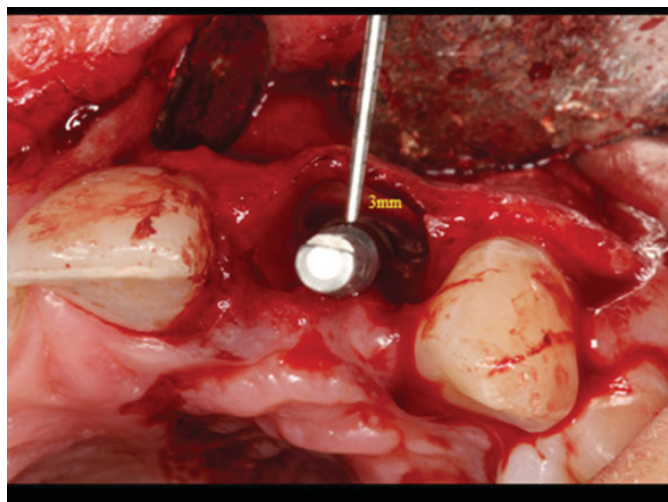


Figure 5: Palatal positioning favorable for regeneration.

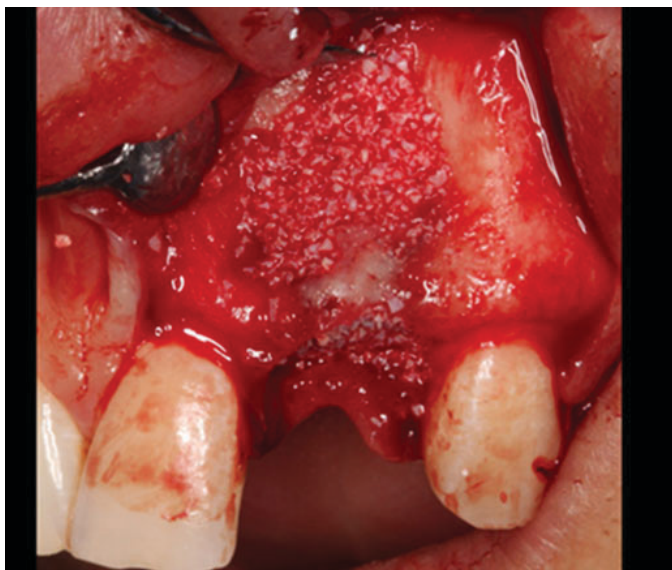

Figure 6: Filling the gaps with biomaterial.

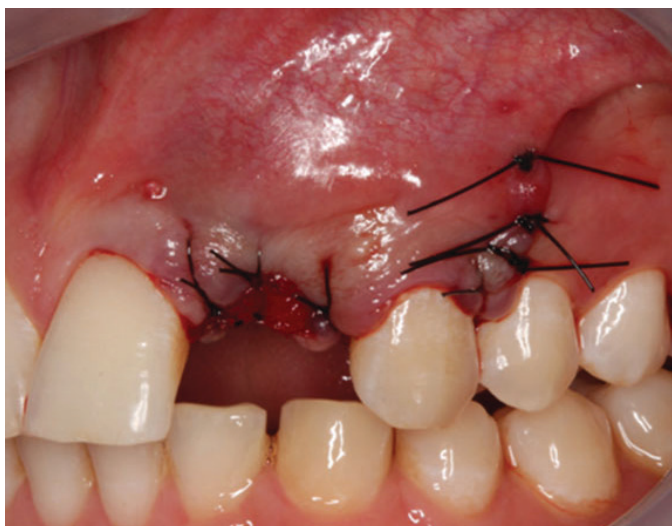


Figure 7: Closure of the wound.

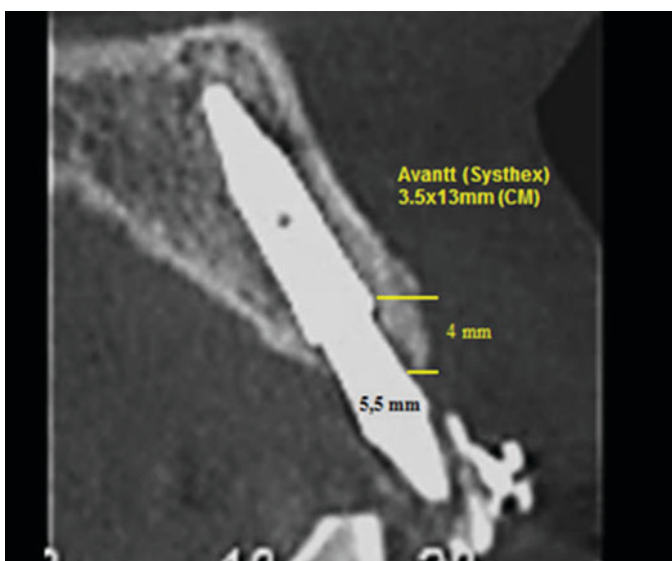


Figure 8: Radiographic view showing the complete reconstruction of the buccal wall.

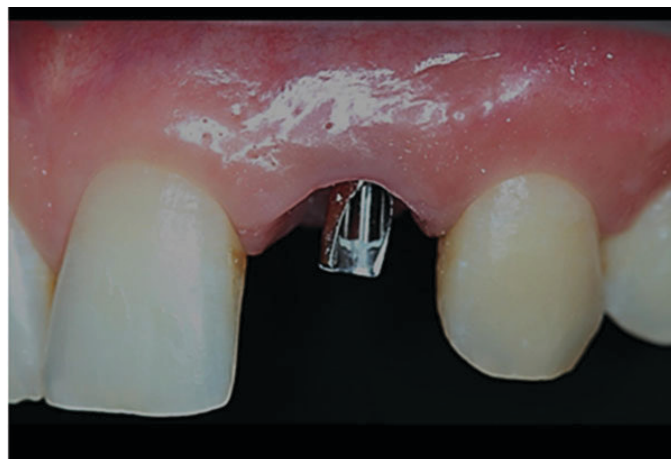

Figure 9: Gingival conditioning obtained with the help of the provisional prosthesis.

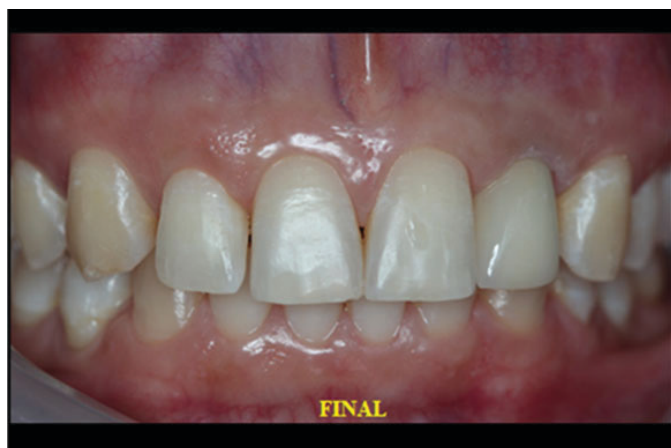

Figure 10: Case completed satisfactorily.

## DISCUSSION

For the placement of an implant in an ideal position, some requirements of soft and hard tissues must be well defined [16]. The authors discuss the best treatment approaches, as well as the limitations associated with aesthetic implant placement.

Since anterior maxilla is in greater demand, the authors evaluated data specifically related to this anatomical region and found several parameters and surgical techniques developed to manipulate soft and hard tissue contours to control the aesthetic result in restorations supported by dental implants in this area. These principles were well defined in this case report, in which a more conservative approach was drawn: extraction, immediate dental implant placement, xenogenous biomaterial grafting, reopening followed by gingival conditioning with the provisional prosthesis and definitive prosthesis in porcelain. This provides a more favorable result in the long run [17].

A randomized controlled trial with 60 partially edentulous patients requiring two single crowns supported by two dental implants was conducted in six different



study centers. For three months the dental implants were randomly placed 0.5 mm or 1.5 mm below the bone crest in aesthetic and non-aesthetic areas according to the divided mouth dental region. Two months after the surgery, the provisional acrylic crowns were replaced by definitive metal-ceramic crowns. Patients were followed up for three years after completion of treatment.

They concluded that considerable clinical differences were not observed when placing implants 0.5 mm or 1.5 mm subcrestal, in relation to aesthetic and non-aesthetic areas [18]. It corroborates with Gualini et al. [19] who in a similar study obtained the same statistical results with the same indications.

In a study [20] with 106 patients who needed a single post-extraction dental implant placement, they were separated as follows: (immediate group; 54 patients), (delayed group; 52 patients). Four months after the preservation of the alveolus the late implants were placed on the delayed group. Dental implants placed with 35 Ncm torque or more were immediately loaded with provisional non-occlusive unitary crowns and then replaced after four months by permanent crowns. As results they obtained: 19 dental implants (35%) were not loaded immediately in the immediate group, against 39 (75%) in the late positioning group, because it was not possible to obtain a 35 Ncm torque or more. No patient gave up. Two dental implants (4%) failed in the immediate group versus none in the delayed group. A higher number of lesser complications occurred in the immediate group (8) in comparison with the delayed group (1). This was statistically significant ( $p = 0.032$ ). Upon delivery of the definitive crowns, four months after loading, the aesthetics were scored at 12.8 and 12.6 in the immediate and late groups, respectively, with no statistically significant difference ( $p = 0.5$ ). Patients in both groups were equally satisfied what is in agreement with other authors [21–23] and with the case reported in this study, where the late loading did not present any problems after the delivery of the definitive prosthesis, and the patient was very satisfied with the aesthetics.

In a systematic review the authors [24] identified 30 eligible studies. A total of 3049 dental implants were placed in a total of 1435 patients, with a mean of 46.68 years age and a minimum of six months of follow-up. The survival rate of delayed loading dental implants (98.38%) was significantly higher than immediate loading dental implants (95.21%) ( $p = 0.001$ ). For marginal bone loss ( $p = 0.32$ ), dental implant stability coefficients ( $p = 0.44$ ), and pocket probe depth ( $p = 0.94$ ), there was no significant difference between delayed and immediate loading.

Immediate dental implants placed in newly extracted areas should be performed with caution, due to significantly lower survival rates than late dental implants placed in healed cavities. This is in agreement with another author who, in a study with 8241 dental implants placed in alveolus, obtained (330 failures, 4.00%) in contrast to 19,410 dental implants in healed sites (599

failures, 3.09%). It is suggested that the placement of dental implants in fresh alveolus affects failure rates [25, 26].

It is very important to mention that soft tissue manipulation is an important step in the aesthetic rehabilitation process, as was well described in [27], that found that granulation tissue originating from the periodontal ligament or connective tissue originally covered by keratinized epithelium has the potential to induce keratinization. However, it also appears that the deep palatal connective tissue may not have the same potential to induce keratinization as the palatal connective tissue originating from an immediately subepithelial area. Approximately 14 days after surgery the peri-implant soft connective tissue already resembles a scar tissue in the original composition, due to the orientation of the fibers and vascularization. On the other hand, the peri-implant supra crestal epithelium can reach a greater final length under certain conditions, such as dental implants placement in fresh sockets, which was well observed in this case and demonstrated by other authors [28–32].

## CONCLUSION

We can conclude that by observing the techniques based on the existing literature, the use of a Cone Morse dental implant generates a better prosthetic result, with the surrounding soft tissues behaving more favorably for an aesthetic format more compatible with current standards.

## REFERENCES

1. Tarnow D, Elian N, Fletcher P, et al. Vertical distance from the crest of bone to the height of the interproximal papilla between adjacent implants. *J Periodontol* 2003;74(12):1785–8.
2. Benic GI, Mir-Mari J, Hämmerle CH. Loading protocols for single-implant crowns: A systematic review and meta-analysis. *Int J Oral Maxillofac Implants* 2014;29:222–38.
3. Leblebicioglu B, Rawal S, Mariotti A. A review of the functional and esthetic requirements for dental implants. *J Am Dent Assoc* 2007;138(3):321–9.
4. Babu PJ, Alla RK, Alluri VR, Datla SR, Konakanchi A. Dental ceramics: Part I – An overview of composition, structure and properties. *American Journal of Materials Engineering and Technology* 2015;3(1):13–8.
5. Slagter KW, Meijer HJA, Bakker NA, Vissink A, Raghoobar GM. Feasibility of immediate placement of single-tooth implants in the aesthetic zone: A 1-year randomized controlled trial. *J Clin Periodontol* 2015;42(8):773–82.
6. Huynh-Ba G, Meister DJ, Hoders AB, et al. Clinical and patient-centered outcomes of immediately placed implants (Type 1) and early placed implants (Type 2): Preliminary 3-month results of an ongoing randomized controlled clinical trial. *Clin Oral*

- Implants Res 2016;27(2):241–52.
7. Kolinski ML, Cherry JE, McAllister BS, Parrish KD, Pumphrey DW, Schroering RL. Evaluation of a variable-thread tapered implant in extraction sites with immediate temporization: A 3-year multicenter clinical study. *J Periodontol* 2014;85(3):386–94.
  8. Lang NP, Zitzmann NU. Working group 3 of the VEWOP. Clinical research in implant dentistry: Evaluation of implant-supported restorations, aesthetic and patient-reported outcomes. *J Clin Periodontol* 2012;39(12):133–8.
  9. Gupta G, Gupta R, Gupta N, Gupta U. Crown lengthening procedures-A review article. *IOSR Journal of Dental and Medical Sciences* 2015;14(4):27–37.
  10. Chun YP, Raffelt C, Pfeiffer H, et al. Restoring strength of incisors with veneers and full ceramic crowns. *J Adhes Dent* 2010;12(1):45–54.
  11. Fava J, Lin M, Zahran M, Jokstad A. Single implant-supported crowns in the aesthetic zone: Patient satisfaction with aesthetic appearance compared with appraisals by laypeople and dentists. *Clin Oral Implants Res* 2015;26(10):1113–20.
  12. De Carvalho PFM, Joly JC, Da Silva RC, González-Martín O. Therapeutic alternatives for addressing pink esthetic complications in single-tooth implants: A proposal for a clinical decision tree. *J Esthet Restor Dent* 2019;31(5):403–14.
  13. Tischler M. Dental implants in the aesthetic zone. *Dent Today* 2016;35(1):104,106.
  14. Brum IS, de Carvalho JJ, Pires JLS, de Carvalho MAA, Santos LBF, Elias CN. Nanosized hydroxyapatite and  $\beta$ -tricalcium phosphate composite: Physico-chemical, cytotoxicity, morphological properties and in vivo trial. *Sci Rep* 2019;9(1):19602.
  15. Brum IS, De Carvalho MAA, Santos PGPD, Devita RL, Pires JLS, de Carvalho JJ. Ultrastructural characterization of the titanium surface degree IV in dental implant aluminum free (Acid Attack). *Journal of Biomaterials and Nanobiotechnology* 2020;11:151–160.
  16. Kutkut A, Andreana S, Monaco E. Esthetic consideration for alveolar socket preservation prior to implant placement: Description of a technique and 80-case series report. *Gen Dent* 2012;60(6):e398–403.
  17. Canellas JVDS, Medeiros PJD, Figueredo CMS, Fischer RG, Ritto FG. Which Is the best choice after tooth extraction, immediate implant placement or delayed placement with alveolar ridge preservation? A systematic review and meta-analysis. *J Craniomaxillofac Surg* 2019;47(11):1793–1802.
  18. Schrott A, Riggi-Heiniger M, Maruo K, Gallucci GO. Implant loading protocols for partially edentulous patients with extended edentulous sites--A systematic review and meta-analysis. *Int J Oral Maxillofac Implants* 2014;29 Suppl:239–55.
  19. Gualini F, Salina S, Rigotti F, et al. Subcrestal placement of dental implants with an internal conical connection of 0.5 mm versus 1.5 mm: Outcome of a multicentre randomised controlled trial 1 year after loading. *Eur J Oral Implantol* 2017;10(1):73–82.
  20. Salina S, Gualini F, Rigotti F, et al. Subcrestal placement of dental implants with an internal conical connection of 0.5 mm versus 1.5 mm: Three-year after loading results of a multicentre within-person randomised controlled trial. *Int J Oral Implantol (Berl)* 2019;12(2):155–67.
  21. Felice P, Pistilli R, Barausse C, Trullenque-Eriksson A, Esposito M. Immediate non-occlusal loading of immediate post-extractive versus delayed placement of single implants in preserved sockets of the anterior maxilla: 1-year post-loading outcome of a randomised controlled trial. *Eur J Oral Implantol Winter* 2015;8(4):361–72.
  22. Esposito M, Zucchelli G, Cannizzaro G, et al. Immediate, immediate-delayed (6 Weeks) and delayed (4 Months) post-extractive single implants: 1-year post-loading data from a randomised controlled trial. *Eur J Oral Implantol* 2017;10(1):11–26.
  23. Bavetta G, Bavetta G, Randazzo V, et al. A Retrospective study on insertion torque and implant stability quotient (ISQ) as stability parameters for immediate loading of implants in fresh extraction sockets. *Biomed Res Int* 2019;2019:9720419.
  24. Felice P, Soardi E, Piattelli M, Pistilli R, Jacotti M, Esposito M. Immediate non-occlusal loading of immediate post-extractive versus delayed placement of single implants in preserved sockets of the anterior maxilla: 4-month post-loading results from a pragmatic multicentre randomised controlled trial. *Eur J Oral Implantol* 2011;4(4):329–44.
  25. Mello CC, Lemos CAA, Verri FR, Santos DMD, Goiato MC, Pellizzer EP. Immediate implant placement into fresh extraction sockets versus delayed implants into healed sockets: A systematic review and meta-analysis. *Int J Oral Maxillofac Surg* 2017;46(9):1162–77.
  26. Han CH, Mangano F, Mortellaro C, Park KB. Immediate loading of tapered implants placed in postextraction sockets and healed sites. *J Craniofac Surg* 2016;27(5):1220–7.
  27. Chrcanovic BR, Albrektsson T, Wennerberg A. Dental implants inserted in fresh extraction sockets versus healed sites: A systematic review and meta-analysis. *J Dent* 2015;43(1):16–41.
  28. Sculean A, Gruber R, Bosshardt DD. Soft tissue wound healing around teeth and dental implants. *J Clin Periodontol* 2014;41 Suppl 15:S6–22.
  29. Tomasi C, Tessarolo F, Caola I, Wennström J, Nollo G, Berglundh T. Morphogenesis of peri-implant mucosa revisited: An experimental study in humans. *Clin Oral Implants Res* 2014;25(9):997–1003.
  30. Zhang C, Tan CK, McFarlane C, Sharma M, Tan NS, Kambadur R. Myostatin-null mice exhibit delayed skin wound healing through the blockade of transforming growth factor- $\beta$  signaling by decorin. *Am J Physiol Cell Physiol* 2012;302(8):C1213–25.
  31. Schapher M, Wendler O, Gröschl M. Salivary cytokines in cell proliferation and cancer. *Clin Chim Acta* 2011;412(19–20):1740–8.
  32. Mueller CK, Thorwarth M, Chen J, Schultze-Mosgau S. A Laboratory study comparing the effect of ridge exposure using tissue punch versus mucoperiosteal flap on the formation of the implant-epithelial junction. *Oral Surg Oral Med Oral Pathol Oral Radiol* 2012;114(5 Suppl):S41–5.

\*\*\*\*\*

## Author Contributions

João Carlos Amorim Lopes – Conception of the work, Drafting the work, Final approval of the version to be published, Agree to be accountable for all aspects of the work in ensuring that questions related to the accuracy or integrity of any part of the work are appropriately investigated and resolved

Saulo Henrique Salviano – Conception of the work, Design of the work, Drafting the work, Revising the work critically for important intellectual content, Final approval of the version to be published, Agree to be accountable for all aspects of the work in ensuring that questions related to the accuracy or integrity of any part of the work are appropriately investigated and resolved

Marco Antônio Carvalho – Conception of the work, Revising the work critically for important intellectual content, Final approval of the version to be published, Agree to be accountable for all aspects of the work in ensuring that questions related to the accuracy or integrity of any part of the work are appropriately investigated and resolved

Jorge José de Carvalho – Conception of the work, Design of the work, Drafting the work, Revising the work critically for important intellectual content, Final approval of the version to be published, Agree to be accountable for all aspects of the work in ensuring that questions related to the accuracy or integrity of any part of the work are appropriately investigated and resolved

Renan Lana Devita – Conception of the work, Analysis of data, Drafting the work, Revising the work critically for important intellectual content, Final approval of the version to be published, Agree to be accountable for all aspects of the work in ensuring that questions related to the accuracy or integrity of any part of the work are appropriately investigated and resolved

Pablo Dallario Ramalho Lucas – Acquisition of data, Analysis of data, Drafting the work, Revising the work

critically for important intellectual content, Final approval of the version to be published, Agree to be accountable for all aspects of the work in ensuring that questions related to the accuracy or integrity of any part of the work are appropriately investigated and resolved

Igor da Silva Brum – Conception of the work, Drafting the work, Revising the work critically for important intellectual content, Final approval of the version to be published, Agree to be accountable for all aspects of the work in ensuring that questions related to the accuracy or integrity of any part of the work are appropriately investigated and resolved

## Guarantor of Submission

The corresponding author is the guarantor of submission.

## Source of Support

None.

## Consent Statement

Written informed consent was obtained from the patient for publication of this article.

## Conflict of Interest

Authors declare no conflict of interest.

## Data Availability

All relevant data are within the paper and its Supporting Information files.

## Copyright

© 2020 João Carlos Amorim Lopes et al. This article is distributed under the terms of Creative Commons Attribution License which permits unrestricted use, distribution and reproduction in any medium provided the original author(s) and original publisher are properly credited. Please see the copyright policy on the journal website for more information.