

Maxillary Ridge Augmentation With Fresh-Frozen Bone Allografts

*Cintia Mussi Milani Contar, DDS, MS,**

João Rodrigo Sarot, DDS, MS,† Jayme Bordini, Jr, DDS, PhD,‡

Gustavo Holtz Galvão, DDS,§ Gastão Vale Nicolau, DDS, MS,|| and

Maria Angela Naval Machado, DDS, PhD¶

Purpose: The present investigation clinically and histologically evaluated the use of fresh-frozen bone in the reconstruction of maxillary alveolar ridges to confirm the effective bone fill and support for the placement of dental implants.

Patients and Methods: Fifteen patients who had atrophic maxillary ridge necessitating bone block grafts prior to implant placement were submitted to maxillary reconstructions performed with human block grafts of tibia fresh-frozen chips. Nine months later the re-entry procedures were carried out and at this time a bone core was removed from the grafts for histological analysis.

Results: Thirty-four blocks were placed, and the number of blocks each patient received ranged from 1 to 4. During the re-entry procedures, all of the grafts were found to be firm in consistency, well-incorporated, and vascularized. A total of 51 implants were placed over the grafts with a minimum of 40-Newton torque in all cases. None of the implants were lost. The follow-up period ranged from 24 to 35 months. The histological analysis revealed a living bone that showed features characteristic of mature and compact osseous tissue surrounded by marrow spaces.

Conclusion: Bone allografts can be successful as graft material for the treatment of maxillary ridge defects. If adequate surgical techniques are adopted, this type of bone graft can be safely used in regions of implant placement as a suitable alternative to autogenous grafts.

© 2009 American Association of Oral and Maxillofacial Surgeons

J Oral Maxillofac Surg 67:1280-1285, 2009

Bone grafting is essential for the repair of bone defects caused by tumors, trauma, loosening of prosthetic joints, and prior dental implant placement in cases of alveolar ridge resorption.¹⁻³ It is intended to stimulate bone healing and fill bone defects, with autologous bone grafting being the standard method of achieving these goals.⁴ Rapid incorporation and consolidation with a lack of immunologic considerations make bone harvested from the patient ideal.⁵ However, limited supply, donor site morbidity, in-

creased blood loss, operative time, cost, and length of hospital stay are the main drawbacks of bone autografts.^{4,6}

The use of bone allograft provides a reasonable alternative to meet the growing need for primary or supplementary graft material. The first bone allograft was performed in 1880 by a Scottish surgeon who successfully reconstructed the infected humerus of a 4-year-old boy with a graft obtained from the tibia of a child with rickets.⁷ Transplantation of large, fresh

*Postgraduate Student, Center for Health and Biological Sciences, Pontifícia Universidade Católica do Paraná, Curitiba, Brazil.

†Postgraduate Student, Department of Implantology, Universidade Federal de Santa Catarina, Florianópolis, Brazil.

‡Professor, Department of Stomatology, Universidade Federal do Paraná, Curitiba, Brazil.

§Implantologist, Private Practice, Curitiba, Brazil.

||Professor and Chief, Postgraduation Course of Implantology, Universidade Federal do Paraná, Curitiba, Brazil.

¶Chairman, Center for Health and Biological Sciences, School of Dentistry, Pontifícia Universidade Católica do Paraná, Curitiba, Brazil.

This research was supported by the Brazilian Agency for Scientific and Technological Development (Conselho Nacional de Desenvolvimento Científico e Tecnológico-CNPq) process No. 475517/2008-5.

Address correspondence and reprint requests to Dr Contar: Av Silva Jardim, 345580. 240-021, Curitiba, PR, Brazil; e-mail: cintiacontar@hotmail.com

© 2009 American Association of Oral and Maxillofacial Surgeons

0278-2391/09/6706-0021\$36.00/0

doi:10.1016/j.joms.2008.11.010

segments of long bone allografts continued and was expanded over the next 90 years.⁸ The establishment of the US Navy Tissue Bank in 1949 marked the emergence of the modern tissue bank.⁹ There is currently an increasing interest in bone allografts as a result of the development of bone banks in many countries.¹⁰

Clinically, the most useful banked allografts are fresh-frozen, freeze-dried, and demineralized bone.¹¹ Fresh-frozen bone is harvested aseptically from live or cadaveric donors and then frozen. It is available for human recipients after at least 6 months of quarantine at -80°C .¹² There is no additional preparation, and the osteoinductive proteins are preserved.¹³ Frozen bone is available as cancellous granules, corticocancellous granules, and cortical granules or chips. Once thawed, it has the same handling qualities as does fresh bone.¹¹

The advantages of using bone allografts include convenience for the surgeon, decreased operative trauma for the patient, an almost unlimited supply of reconstructive material, decreased blood loss, absence of donor site morbidity, and decreased operative time.^{11,13} One of the main concerns with the use of bone allograft is transmission of infection, most notably hepatitis and acquired immunodeficiency syndrome.¹⁴ Guidelines on donor selection, tissue procurement, tissue preservation, tissue storage, and adequate record-keeping procedures have been designed by bone banks to ensure the supply of safe allogeneic bone.^{15,16} Another concern with bone allograft is its antigenicity. Either freeze-drying or freezing bone to -20°C significantly reduces this risk.⁶

In the orthopedics field one current trend shows surgeons using allografts as substitutes for autografts.¹⁰ Nevertheless, there is limited information about the use of allografts in maxillofacial procedures. This investigation clinically and histologically evaluated the use of fresh-frozen bone in the reconstruction of maxillary alveolar ridges to confirm the effective bone fill and support for the placement of dental implants.

Patients and Methods

PATIENT SELECTION AND RECONSTRUCTIVE SURGICAL PROCEDURE

From April 2005 to March 2006, 15 patients from the postgraduate course in implantology at the Universidade Federal do Paraná, Curitiba, Brazil, who had atrophic maxillary ridge necessitating bone block grafts before implant placement were admitted to this study. Patients without sufficient compliance with therapy and patients with systemic medical conditions were excluded. There were 6 men and 9 men in the group, and the mean age was 44 years, with ages ranging from 29 to 61 years. The maxillary reconstruc-

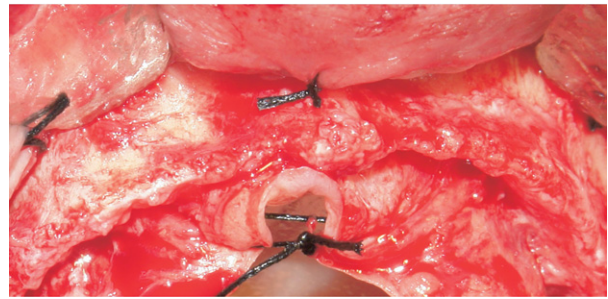


FIGURE 1. Operative view of accentuated maxillary ridge resorption.

Contar et al. Maxillary Ridge Augmentation With Allograft. J Oral Maxillofac Surg 2009.

tions were performed with human block grafts of tibia fresh-frozen chips obtained from the Clinics Hospital Tissue Bank of Universidade Federal do Paraná.

Approval for this study was obtained from the Ethics Committee in Research at Pontifícia Universidade Católica do Paraná (Curitiba, Brazil). All subjects signed a consent form to participate in the study.

The maxillary ridge resorption was diagnosed through clinical and radiologic examination. Panoramic radiographs and routine blood examinations were performed for all patients and did not show any other bone or systemic diseases.

All patients followed an antibiotic regimen of 2 g of amoxicillin (Amoxil; GlaxoSmithKline, Rio de Janeiro, Brazil) and 8 mg of dexamethasone (Decadron; Aché Pharmaceutical Laboratories, Guarulhos, Brazil) 1 hour before surgery.

The bone was thawed for 1 hour, and then the blocks were sculpted with chisels and rotary instruments. An appropriate local anesthetic (4% articaine with 1:100,000 epinephrine; DFL, Rio de Janeiro, Brazil) was administered, and a full-thickness mucoperiosteal flap was elevated (Fig 1). After careful site preparation, which included decortication of the maxilla in the defect site to enhance marrow space bleeding, the blocks were perfectly adapted to the maxillary wall without any gap. Fixation with miniscrews (Neodent, Curitiba, Brazil) was used for stabilization of the prepared blocks at the recipient site. The miniscrews were placed through the central portion of the blocks and rested in the palatal portion of the defect to prevent micromovement of the graft. The flaps were repositioned without tension and silk sutures (No. 4.0; Ethicon, Somerville, NJ) were used for closure. The patients continued taking 1 g of amoxicillin every 12 hours for 7 days and 4 mg of dexamethasone every 8 hours for 2 days and performed regular chlorhexidine rinses (Periogard; Colgate-Palmolive, São Paulo, Brazil) twice daily starting the day after surgery. The sutures were removed 7 days after surgery, and at that time the patients were evaluated for infection and

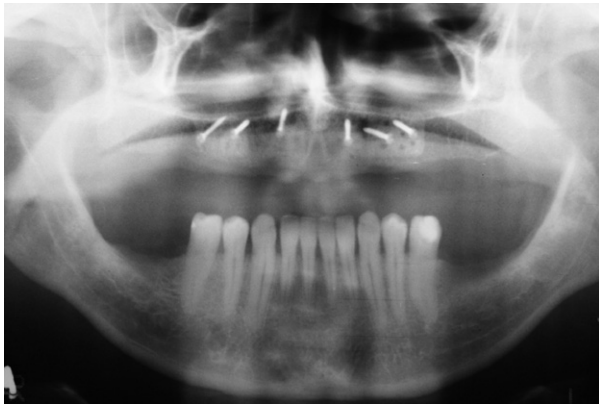

FIGURE 2. Panoramic radiograph showing graft incorporation.
Contar et al. Maxillary Ridge Augmentation With Allograft. J Oral Maxillofac Surg 2009.

wound dehiscence. During the healing period, all patients were seen once a month until the time of implant placement.

In the third postoperative month a panoramic radiograph was obtained to evaluate the graft's incorporation (Fig 2). The reopening surgery was carried out at a mean of 9 months after bone grafting, ranging from 8 to 11 months (Fig 3). At that time, 1 bone core from the graft was removed with a trephine bur from the area where 1 implant would be placed for histologic analysis. Next, the miniscrews were removed, and titanium implants (Systhex Sistema de Implantes Osseointegrados, Curitiba, Brazil) were placed (Fig 4). Additional grafting was not required at the time of implant installation for any of the patients, and none of the graft blocks were dislodged at this time. Panoramic radiographs were routinely obtained in the first and sixth (Fig 5) postoperative months to evaluate the implants' osseointegration.

The bone specimens were routinely processed for serial decalcified sections. The specimens were fixed in 10% neutral-buffered formaldehyde solution for 48 hours and demineralized in 5% trichloroacetic acid for

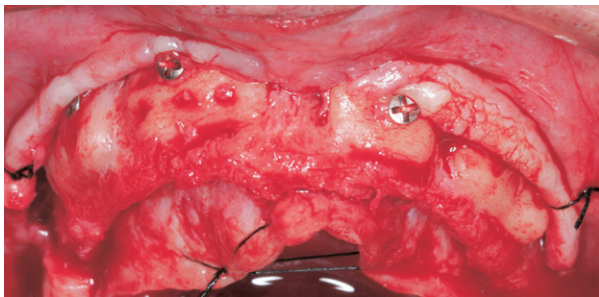


FIGURE 3. Operative view during reopening of area showing excellent integration of grafts.
Contar et al. Maxillary Ridge Augmentation With Allograft. J Oral Maxillofac Surg 2009.

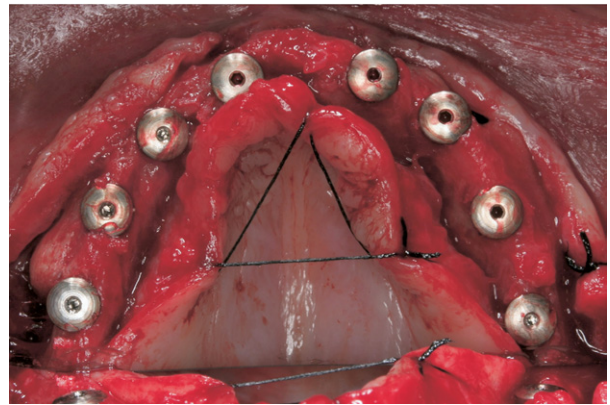


FIGURE 4. The new bone received 8 implants symmetrically placed.
Contar et al. Maxillary Ridge Augmentation With Allograft. J Oral Maxillofac Surg 2009.

15 days. Subsequently, they were embedded in paraffin, and 6- μ m thin sections were obtained and stained with hematoxylin-eosin and Masson trichrome stain for the histologic analysis. The sections were examined by light microscopy.

Results

We placed 34 blocks, and the number of blocks that each patient received ranged from 1 to 4; the number of implants ranged from 1 to 8.

For all patients, the medications prescribed were effective for pain and edema. The healing period was uneventful for 14 patients. One patient had early exposition of the block that required a second surgical procedure to cover it. This occurred because of inadequate flap design during the first surgery. Although its exposition was premature, there was no

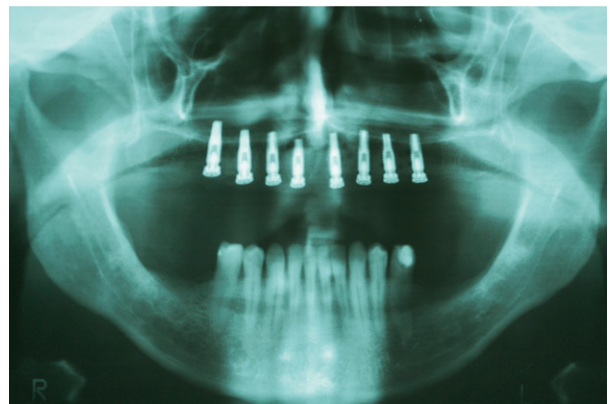


FIGURE 5. Panoramic radiograph showing osseointegrated implants in grafted areas.
Contar et al. Maxillary Ridge Augmentation With Allograft. J Oral Maxillofac Surg 2009.

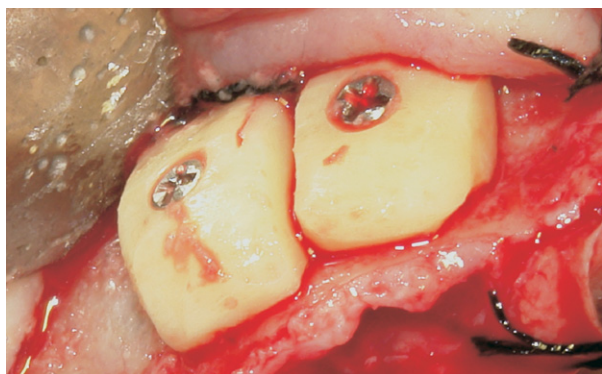


FIGURE 6. Operative view after fixation of 2 bone block allografts with miniscrews.

Contar et al. Maxillary Ridge Augmentation With Allograft. J Oral Maxillofac Surg 2009.

infection and no compromise of the final result. None of the other grafts became exposed or infected.

During the re-entry procedures, all of the grafts were found to be firm in consistency and well-incorporated and vascularized, even in cases involving larger reconstructions. Some bone resorption was observed in the grafted materials, but all implants were placed as initially planned (Figs 6, 7). There was no excessive bone resorption in any case that could make changing the treatment plan necessary.

A total of 51 implants were placed over the grafts with a minimum of 40 N of torque in all cases. Twenty-two implants were already accompanied by implant-supported restorations (Figs 8, 9). None of the implants were lost. The follow-up period ranged from 24 to 35 months.

Histologic analysis of the bone specimens removed during the re-entry procedures showed living bone that showed features characteristic of mature and

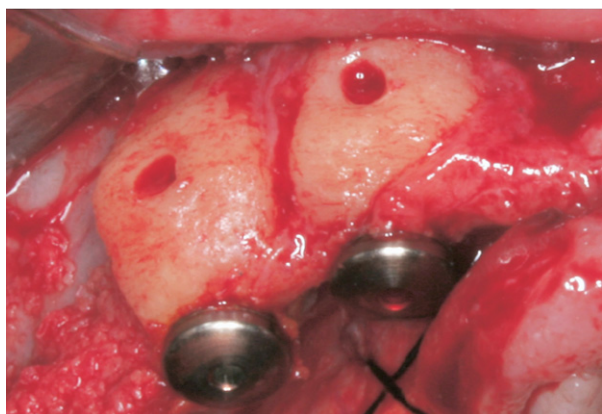


FIGURE 7. Re-entry procedure performed at 9 months for implant placement. The bone remodeling of the grafted blocks should be noted.

Contar et al. Maxillary Ridge Augmentation With Allograft. J Oral Maxillofac Surg 2009.

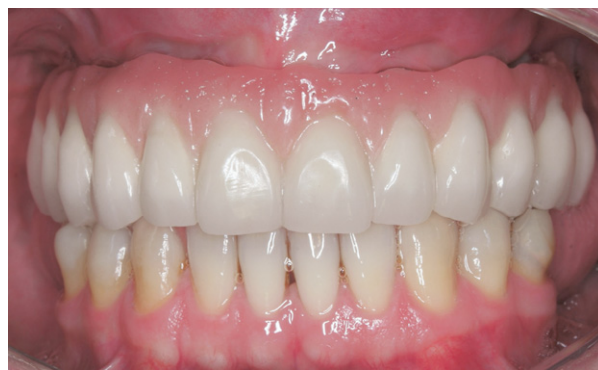

FIGURE 8. Final restoration.

Contar et al. Maxillary Ridge Augmentation With Allograft. J Oral Maxillofac Surg 2009.

compact osseous tissue surrounded by marrow spaces (Fig 10). Viable bone was observed, as well as newly formed bone incorporated with the grafted areas.

Discussion

Transplanting bone from one human to another is an idea that has been with us for hundreds of years and circumvents the problems with autogenous bone grafting.⁵ Allografts have been used in orthopedics for a long time, in many applications including trauma, spine fusion, revision arthroplasty, tumor surgery, and non-union.^{10,17} In a prospective trial in scoliosis surgery, the authors concluded that even in the presence of an adequate autogenous iliac crest, the use of frozen bank bone was superior.⁶ The use of autografts in orthopedic surgery is currently becoming rarer, given the availability of safe and efficient bone allografts.¹⁰

The disadvantages of allografts, such as disease transmission and antigenicity, have been widely studied and represent a minimal risk to the patient.⁶ With the standard protocols applied by the bone banks, the risk of viral transmission by unprocessed deep-frozen,

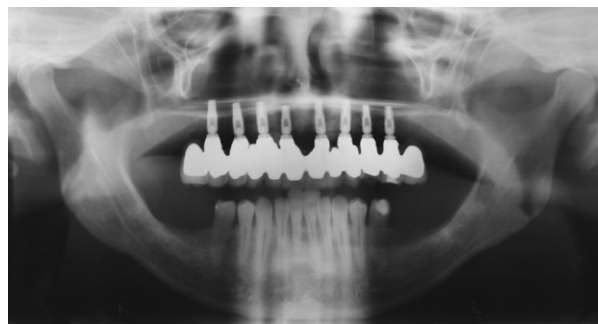

FIGURE 9. Panoramic radiograph showing implant-supported restorations.

Contar et al. Maxillary Ridge Augmentation With Allograft. J Oral Maxillofac Surg 2009.

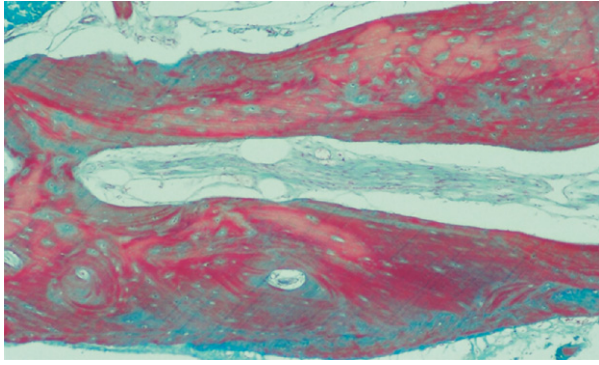


FIGURE 10. Mature and compact osseous tissue surrounded by marrow spaces (Masson trichrome stain, original magnification $\times 100$).

Contar et al. *Maxillary Ridge Augmentation With Allograft*. *J Oral Maxillofac Surg* 2009.

nonirradiated grafts from screened donors is currently less than 1:200,000 for hepatitis C virus and 1:1 million for human immunodeficiency virus.¹⁰ It is virtually nonexistent for processed bone grafts.¹⁰ Nonetheless, freeze-dried or lyophilized grafts possess inferior osteoinductive properties, mechanical properties, and strength compared with frozen grafts.^{14,18} Demineralized bone does not tolerate axial loading,¹¹ having a wide range of applications in dentoalveolar grafting procedures at low-stress areas.¹⁹ As new pathogens emerge or are discovered, the challenge for tissue banks will be to continually revise and improve their practices.⁸

Bone grafts of any type can only regenerate bone through 3 possible mechanisms: direct osteogenesis, osteoconduction, and osteoinduction.²⁰ The only material to date that has true osteogenic properties is autograft.⁴ The ideal allogeneic bone graft material would cause new bone to form (osteoinduction) and provide a scaffold to support the regenerating host bone that will eventually replace the graft (osteoconduction).² The osteoinduction properties of the allografts remain controversial in the literature. In a recent study Simpson et al¹² showed that osteoblast-related cells can be grown in vitro from fresh-frozen allograft specimens after the quarantine period. Other authors confirm that the frozen human bone is prepared so that the nondemineralized bone matrix and the morphogenetic bone proteins are preserved.^{13,21}

Bone allograft procedures are very common at our institution. The use of this kind of graft has clearly increased over the last 3 years, whereas the use of autografts decreased, indicating the same trend seen in the orthopedic field. The minor operative time, unlimited supply, low morbidity, and painless healing period are some of the advantages that encourage us in the growing use of the allografts.

The good results obtained in these 15 patients are in accordance with the cases presented by others authors,^{2,13,21,22} who showed efficacy in using block allografts in areas of dental implant placement. The only complication presented in this study was because of an inadequate surgical technique having no relation with the graft material itself.

The histologic evidence of new bone deposition in allografts was already shown in other cases reported in series^{2,22} and confirmed in this study. Osteocytes encased in a mineral matrix and marrow spaces suggest a new bone incorporation without residual graft material.

Although our follow-up is relatively short, a study of bone allograft with a very long follow-up period (30-35 years) proves it is a satisfactory and durable method for filling bone defects.¹⁷

The results support the hypothesis that fresh-frozen bone allografts can be successful as graft material for the treatment of maxillary ridge defects. If adequate surgical techniques are adopted, this type of bone graft can be safely used in regions of implant placement as a suitable alternative to autogenous grafts.

Future studies using fresh-frozen bone allograft, especially with long-term follow-up, are needed to learn about the behavior of this material after longer periods with occlusal loading.

References

- Hofman A, Konrad L, Hessmann MH, et al: The influence of bone allograft processing on osteoblast attachment and function. *J Orthop Res* 23:846, 2005
- Leonetti J, Koup R: Localized maxillary ridge augmentation with a block allograft for dental implant placement: Case reports. *Implant Dent* 12:217, 2003
- Hachiya Y, Sakai T, Narita Y, et al: Status of bone banks in Japan. *Transplant Proc* 31:2032, 1999
- Ilan DI, Ladd AL: Bone graft substitutes. *Oper Tech Plast Reconstr Surg* 9:151, 2003
- Williams A, Szabo R: Bone transplantation. *Orthopedics* 27:488, 2004
- Dodd CAF, Fergusson CM, Freedman L, et al: Allograft versus autograft bone in scoliosis surgery. *J Bone Joint Surg Br* 70:431, 1988
- De Boer H: The history of bone grafts. *Clin Orthop Relat Res* 292, 1968
- Tomford W: Bone allografts: Past, present and future. *Cell Tissue Bank* 1:105, 2000
- Leslie H, Bottenfield S: Donation, banking, and transplantation of allograft tissues. *Nurs Clin North Am* 24:891, 1989
- Albert A, Leemruse T, Druetz V, et al: Are bone autografts still necessary in 2006? A three-year retrospective study of bone grafting. *Acta Orthop Belg* 72:734, 2006
- Hardin C: Banked bone. *Otolaryngol Clin North Am* 27:911, 1994
- Simpson D, Kakarala G, Hampson K, et al: Viable cells survive in fresh frozen human bone allografts. *Acta Orthop* 78:26, 2007
- Perrott DH, Smith RA, Kabam LB: The use of fresh frozen allogeneic bone for maxillary and mandibular reconstruction. *Int J Oral Maxillofac Surg* 21:260, 1992
- Gazdag AR, Lane JM, Glaser D, et al: Alternative to autogenous bone graft: Efficacy and indications. *J Am Acad Orthop Surg* 3:1, 1995

15. Tomford WW, Doppelt SH, Mankin HJ, et al: Bone bank procedures. *Clin Orthop Relat Res* 15, 1983
16. Palmer SH, Gibbons CLMH, Athanasou NA: The pathology of bone allograft. *J Bone Joint Surg Br* 81:333, 1999
17. Steinberg EL, Luger E, Zwas T, et al: Very long-term radiographic and bone scan results of frozen autograft and allograft bone grafting in 17 patients (20 grafts) a 30- to 35-year follow-up. *Cell Tissue Bank* 5:97, 2004
18. Ehrler DM, Vaccaro AR: The use of allograft bone in lumbar spine surgery. *Clin Orthop Relat Res* 38, 2000
19. Kao ST, Scott DD: A review of bone substitutes. *Oral Maxillofac Surg Clin North Am* 19:513, 2007
20. Marx RE: Bone and bone graft healing. *Oral Maxillofac Surg Clin North Am* 19:455, 2007
21. Accetturi E, Germani KB, Cavalca D: Reconstruction of bone defects in the maxilla and mandibula through the use of frozen human bone. *Transplant Proc* 34:531, 2002
22. Petrunaro PS, Amar S: Localized ridge augmentation with allogenic block grafts prior to implant placement: Case reports and histologic evaluations. *Implant Dent* 14:139, 2005