

Minimally Invasive Surgery for Horizontal Ridge Augmentation (Subperiosteal Tunneling): A Case Report

Roberto Miers¹, Helton Panisson¹, Norival Francisco de Souza Junior¹, Márcio Adriano Vavassori¹, Thais Ustulin Fuzer², Túlio Del Conte Valcanaia³, Guenther Schuldt Filho¹

¹São Leopoldo Mandic College/ Curitiba PR Unit

²School of Dentistry of Bauru/ University of São Paulo/ São Paulo SP

³University of Itajaí Valley /Itajaí SC

Abstract: *This case report emphasizes the importance of planning for excellent resolution of complex cases. A female patient wearing a total prosthesis for 20 years exhibited severe horizontal resorption in the premaxillary area, making rehabilitation with implants impossible. The maxilla was regenerated using a lyophilized allogeneic bone from a tissue bank, and subperiosteal tunneling was performed. The technique recovered the lost bone thickness after dental extractions, thus allowing the placement of eight implants, five of them in the grafted area. The patient was rehabilitated with a complete fixed prosthesis, recovering function and aesthetics.*

Keywords: Bone Graft, tunneling technique, dental implant, ridge augmentation, minimally invasive surgery, maxillary reconstruction, periosteal cell

1. Introduction

After dental extraction, the process of resorption of the alveolar process begins. After 90 days, resorption of the buccal bone plate occurs in the alveoli filled only with coagulated blood, despite the existing bone formation, causing a significant loss of volume [1, 2, 3]. This loss of volume causes a bone defect, preventing the placement of implants in favorable positions, impairing the function of the teeth, and subsequently compromising the final cosmetic result [4, 5, 6]. Therefore, procedures may be necessary to correct the defects caused by resorption in the alveolar ridge [7].

Autogenous bone has long been considered the gold standard among bone grafting materials due to its osteogenic, osteoinductive, and osteoconductive properties, in addition to its immunocompatibility [7, 8, 9, 10]. However, it has the following limitations in relation to morbidity: increased surgical area, unpredictability regarding resorption, longer surgical time, and quantity restriction [8, 9, 10].

Considering the limitations of the use of autogenous bone, there is a constant search for materials that can be used as bone substitutes. Bone graft substitutes must be biocompatible, nonantigenic, susceptible to sterilization, easy to handle, and have good osteoinductive and osteoconductive properties [7, 9]. Ideally, a material used for grafting should maintain space, be stable, be an osteoconductor, be easy to handle, be predictable from the point of view of resorption, and be susceptible to remodeling [11].

Bone substitutes can be of homologous, heterologous, or alloplastic origin. A homologous graft is a type of graft where the donor is an individual of the same species as the recipient. It has osteoinductive and osteoconductive

properties [9]. It reduces morbidity and surgical time, in addition to unlimited availability [9, 12]. However, it has the following disadvantages: risk of disease transmission, high processing cost, and need for specialized storage sites [7, 13].

Several procedures of bone grafting for regeneration have been reported, such as guided bone regeneration, block grafting, and osteogenic distraction [12]. One of the techniques of guided bone regeneration is subperiosteal tunneling, suggested by Kent et al. In this technique, two vertical incisions are created in the ridge, and the area between them is totally detached, forming a tunnel. The graft material is positioned, and the area is sutured [14, 15]. This allows the bone graft to be covered by an intact periosteum [16]. Because it is minimally invasive, this technique has a shorter surgical time and lower postoperative morbidity [16, 17, 18].

Complete fixed prostheses anchored on implants have been widely used for the rehabilitation of edentulous maxillae and mandibles, and four to six mandibular implants and six to ten maxillary implants are usually placed [19]. To achieve predictability and stability, the planning of the anchoring of the prosthesis on the implant should ensure that the implants are placed in strategic positions, thus allowing the dissipation of applied forces, the balance of the action arms, and strength of the prosthesis [12, 20, 21].

2. Case Presentation

A 44-year-old female patient, nonsmoker and with leucoderma, sought dental care following the major complaint of aesthetic and functional dissatisfaction with the upper total prosthesis used for 20 years.

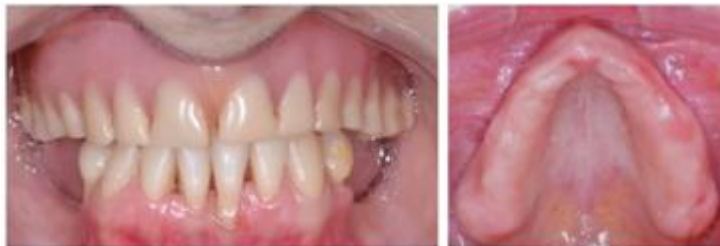

Figure 1: Intraoral pictures of the patient

Anamnesis showed that the patient had good general health and no systemic problem. Intraoral examination revealed resorption of the alveolar ridge (change in thickness). Computed tomography (CT) scan confirmed resorption and showed that the ridge was 2 to 3 mm thick in the premaxillary region, which prevented the placement of implants.

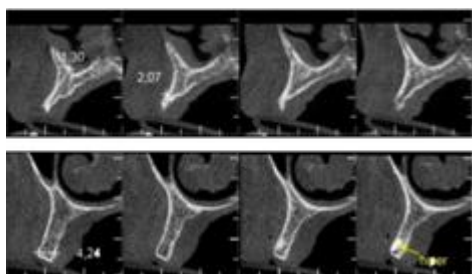


Figure 2: Previous computed tomography images

Increasing the thickness of the maxilla with a homogenous bone graft using the tunneling technique and subsequently placing an implant to create a complete fixed prosthesis were considered the treatment strategies. The patient was administered with 500 mg of amoxicillin (GSK®, England) and 4 mg of dexamethasone (Aché® Laboratórios Farmacêuticos, SA/São Paulo) 1 hour before the surgical procedure. Anesthesia was induced by blocking the infraorbital and greater palatine nerves with mepivacaine 2% with 1:100, 000 epinephrine (Nova DFL®, Rio de Janeiro, RJ).

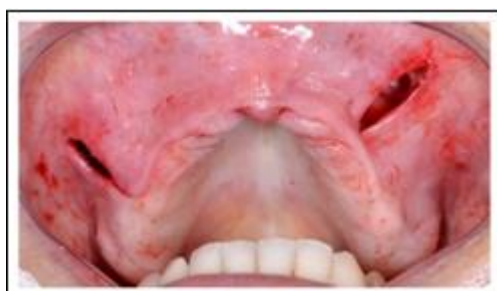

Figure 3: Vertical incisions and tunnel creation

Vertical incisions were created using a #15C blade (Swann-Morton, England) in the areas corresponding to the maxillary canines, followed by careful detachment of the gingival and periosteal tissue to create a tunnel in the grafting area and preserve the integrity of the gingival tissue.

To compensate for bone resorption of the buccal bone plate and enable the placement of implants for the creation of a protocol-type prosthesis, bone grafting was performed with homogenous bone from the tissue bank of the Institute of Orthopedics and Traumatology of the Hospital das Clínicas of the Medical School of the University of São Paulo. The freeze-dried particulate bone used was hydrated in 3-mL rifamycin sodium 10 mg (EMS®, SA/São Paulo) to minimize the risk of infection and promote hydration.

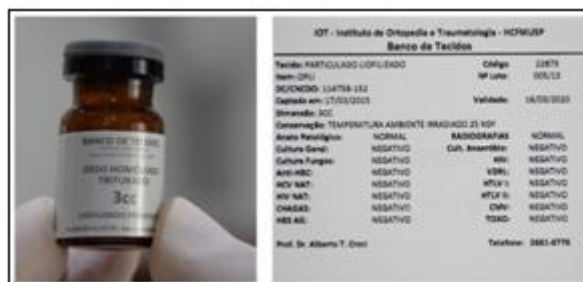

Figure 4: Allogeneic graft obtained from the tissue bank of the Institute of Orthopedics and Traumatology of the Hospital das Clínicas of the Medical School of the University of São Paulo

After being soaked for 5 minutes in the antibiotic solution, the material was inserted and compacted in the recipient site using a Molt elevator.

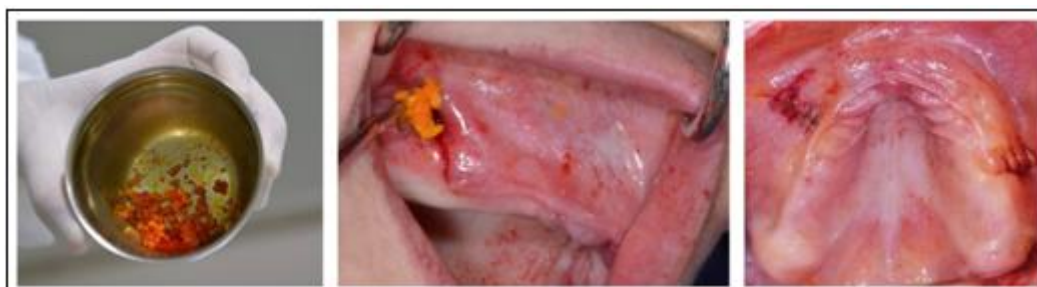

Figure 5: Insertion of the graft and sutures

The area was sutured with a 5.0-mononylon thread (Ethicon®, USA) using simple interrupted stitches.

Two daily doses of 600-mg ibuprofen arginine (Zambon®, Italy) were prescribed to control postoperative pain, and three daily doses of 500-mg amoxicillin (GSK®, England) were prescribed for 7 days to prevent and control infections. The patient also received several healthcare instructions on postoperative care and hygiene maintenance. The stitches were removed after 15 days.

Healing and bone formation were expected to be observed after 5 months, and the patient was monitored monthly to assess the adaptation of the upper total prosthesis and tissue integrity.

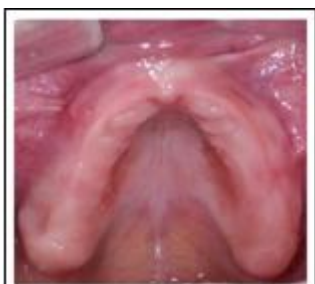

Figure 6: Intraoral photograph of the ridge after the regeneration procedure

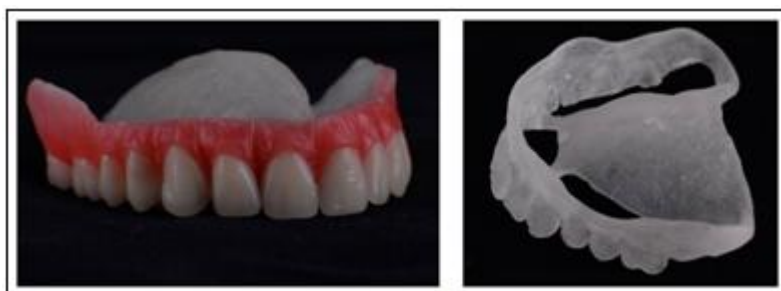

Figure 8: Prosthetic treatment planning and surgical guide

Anesthesia was induced by infraorbital and palatine nerve blockade with mepivacaine 2% with 1:100,000 epinephrine (New DFL®, Rio de Janeiro, RJ). A supracrestal incision and two bilateral relaxing incisions were created in the second molar areas using a #15C blade (Swann-Morton, England). Gingival tissue detachment was performed to preserve the integrity of the gingival tissue.

Eight implants were placed. Classic Ci implants measuring 3.75 x 11.5 mm (Systhex®, Curitiba, PR) were placed in the regions corresponding to teeth 17, 15, 13, 11, 21, 23, and 25, and a classic Ci implant (Systhex®, Curitiba, PR) measuring 3.75 x 10.0 mm was placed in the region corresponding to tooth 27.

Drilling was performed according to the protocol determined by the manufacturer using a lance drill, a 2.0 drill, a 2/3 pilot drill, a 2.8 drill, and a 4.1

After the healing period, a new CT scan was requested to plan the placement of the implants for the creation of the protocol-type prosthesis. The positioning of the implants was defined through reverse planning, and through it, a surgical guide was prepared to assist the milling.

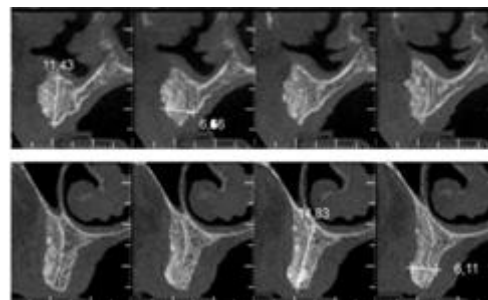


Figure 7: Computed tomography images obtained after a 5-month healing period

The patient was administered with 500 mg of amoxicillin (GSK®, England) and 4 mg of dexamethasone (Aché Laboratórios Farmacêuticos SA, São Paulo) 1 hour before the surgical procedure.

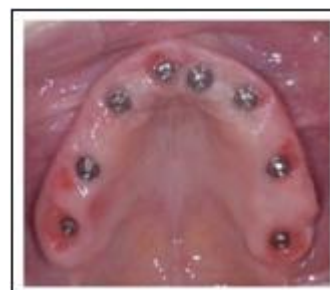

Figure 9: Implants in place

Systhex®/Curitiba, PR, countersink drill.

The area was sutured with 5.0-mononylon thread (Ethicon®, USA) using simple interrupted stitches.

To control postoperative pain, three daily doses of 600 mg of ibuprofen arginine (Zambon®, Italy) and one daily dose of dexamethasone (Aché Laboratórios Farmacêuticos SA, São Paulo) were administered for 2 days. Three daily doses of 500 mg of amoxicillin (GSK®, England) were prescribed for the prevention and control of infections during 7 days. The patient also received several healthcare instructions on

postoperative care and hygiene maintenance. The stitches were removed after 15 days.

Osseointegration was expected to be observed after 5 months, and subsequently, the implants underwent reopening surgery.

Anesthesia was induced by performing the infiltrative technique with mepivacaine 2% with epinephrine 1:100,000 (New DFL®, Rio de Janeiro, RJ). A supracrestal incision and relaxing incisions in the second molar region were created using a #15C blade (Swann-Morton, England).

Mini conical abutments (Systhex®, Curitiba, PR) with 32 N/cm of torque were placed, and protection cylinders (Systhex®, Curitiba, PR) with 10N/cm of torque were subsequently screwed on the components. The patient's complete prosthesis was smoothed and relined using a new base material (Soft Provisório_ TDV Dental Ltda, Pomerode SC).

The area was sutured with 5.0-mononylon thread (Ethicon®, USA) using simple interrupted stitches.

To control postoperative pain, three daily doses of 600 mg of ibuprofen arginine (Zambon®, Italy) were administered.

The patient also received several healthcare instructions on postoperative care and hygiene maintenance. The stitches were removed after 15 days.

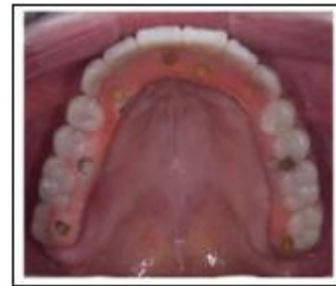

Figure 10: Hybrid, complete-fixed prosthesis in place

After 20 days, the impression copings (Systhex®, Curitiba, PR) were installed and attached with a pattern acrylic resin (GC America INC®, USA). The transfer impression was created using Zetaplus and Oranwash condensation silicone (Zhermack SpA®, Italy).

The test plate for delimitation of the reference lines and determination of the intermaxillary relations was created after 20 days. Seven days later, the teeth were tested, and aesthetic adjustments were made.

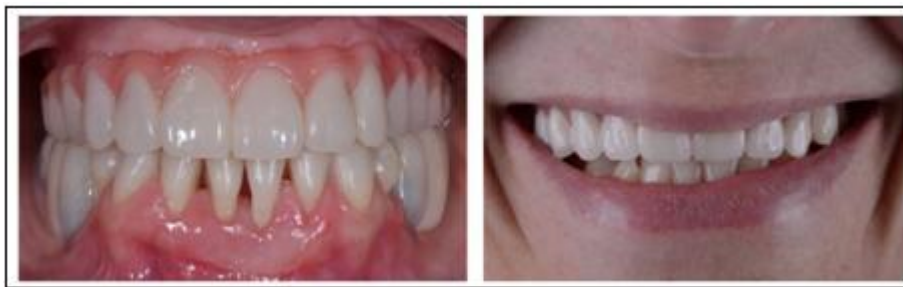

Figure 11: Intra- and extraoral photographs of the final result

The new hybrid complete fixed prosthesis was installed 10 days after the test with a 10 N/cm torque in the hex head screws (Systhex®, Curitiba, PR).

obtained with the treatment. The peri-implant tissues were healthy with no signs and symptoms of inflammation, and bone normality was confirmed with a new cone beam CT scan.

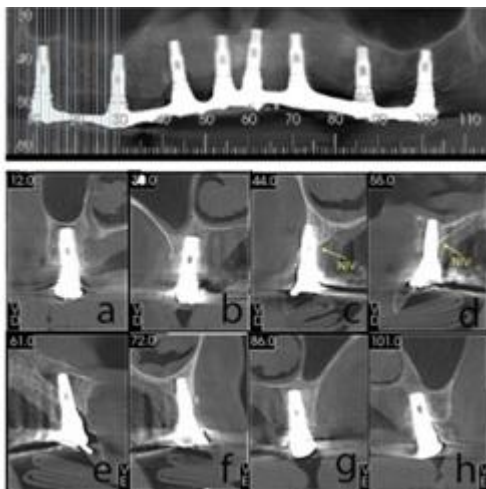


Figure 12: Panoramic X-ray and computed tomography sections of the installed implants

After 18 months with the functioning prosthesis, the patient was satisfied with the functional and aesthetic result

3. Discussion

For a successful implant treatment, the position of implant placement must be consistent with the prosthetic planning performed for the prosthesis to be created [2]. The literature regarding alveolar bone resorption that occurs after tooth extraction is significantly extensive [9]. In view of the need to install implants in ideal positions and the bone loss that occurs after extractions, both preservation and bone recovery procedures have been widely studied [22].

Among the materials available for bone grafting, autogenous bone is considered the gold standard due to its osteogenic, osteoinductive, and osteoconductive properties [23]. However, it has several disadvantages such as higher intraoperative morbidity, availability limited to the donor area, increased surgical time, increased surgical risk, and higher postoperative morbidity [10, 22].

Among the bone substitutes, homologous graft, obtained from the body of another individual of the same species as that of the recipient, has osteoinductive and osteoconductive properties because bone morphogenetic proteins are preserved after processing [24, 25]. The advantages of this type of graft are the elimination of surgery in the donor area, unlimited availability, shorter surgical time, and lower intra- and postoperative morbidity [25]. With the standardization of protocols, the current risk of disease transmission is practically nonexistent, and these grafts are thus considered safe with good applicability [14, 25, 26, 27].

Although the long-term results of allogeneic grafting are similar to those of autogenous grafting, it has higher rates of resorption [10]. To circumvent resorption, allografts can be associated with xenografts, which have osteoconductive capacity and form a good framework because their architecture and composition are similar to those of the human bone [8, 9, 10, 24].

The technique of bone regeneration through periosteal tunneling is performed by creating two vertical incisions to access the bone bed [16]. The use of this type of incision preserves the keratinized gingival mucosa because the incision is limited to the alveolar mucosa [28]. This allows minimal aesthetic changes due to the presence of small scars after the repair process [18]. Additionally, the incidence of changes in muscle contraction is low [18].

In the study by Deeb et al., in which the subperiosteal tunneling technique was compared to the conventional technique using a titanium-reinforced polytetrafluoroethylene membrane, both regenerated with allogeneic bone and bovine hydroxyapatite (1:1), the authors found similar results for bone regeneration; however, the tunneling technique had lower rates of suture dehiscence and graft exposure than the conventional technique. Additionally, it was associated with reduced return visits, reduced time of systemic antibiotic therapy use, and lower costs of treatment.

The periosteum is a richly vascularized connective tissue membrane that covers the bone tissue. In the study by Yang et al., the periosteum and collagen membranes were used as barriers in bone grafts, and bone resorption was evaluated. The authors concluded that both the periosteum and the collagen membrane occluded the graft, thereby preventing resorption.

In the case reported herein, bone regeneration through periosteal tunneling was successful, enabling the installation of eight implants, five of them in the regenerated region, and subsequent creation of a complete fixed prosthesis. After a period of 18 months, the absence of signs and symptoms of inflammation and stability of the periimplant complex are observed.

The resolution of a complex case requires precise planning that takes into consideration the patient's expectations during planning, using scientific evidence to circumvent the inherent limitations, thus providing a treatment that preserves health, function, aesthetics, and stability [20, 21].

4. Conclusion

The resolution of complex cases is challenging for dental surgeons. It requires the surgeon and the prosthodontist to perform a comprehensive approach, aiming to circumvent the limitations and significantly meet the patient's expectations.

In addition to requiring precise planning, the surgeon's knowledge on the surgical techniques and high skill level are essential in these cases. Moreover, it requires the prosthodontist to produce technical works with correct dissipation of forces to provide satisfactory function and aesthetics.

Finally, the stability of the final work is only possible if the patient cooperates by following the recommendations of the healthcare professionals involved in the resolution of the case.

5. Conflicts of Interest

The authors declare that there are no conflicts of interest in relation to the publication of this article.

References

- [1] L. Schropp, A. Wenzel, L. Kostopoulos, and T. Karring, "Bone healing and soft tissue contour changes following single-tooth extraction: a clinical and radiographic 12-month prospective study," *International Journal of Periodontics and Restorative Dentistry*, vol. 23, no.4, pp. 313–323, 2003.
- [2] L. A. Mezzomo, R. S. Shinkai, N. Mardas, and N. Donos, "Alveolar ridge preservation after dental extraction and before implant placement: a literature review," *Revista Odonto Ciencia*, vol. 26, no.1, pp. 77–83, 2011.
- [3] R. V. Lam, "Contour changes of the alveolar processes following extractions," *Journal of Prosthetic Dentistry*, vol. 10, no. 1, pp. 25–32, 1960.
- [4] U. Grunder, "Crestal ridge width changes when placing implants at the time of tooth extraction with and without soft tissue augmentation after a healing period of 6 months: report of 24 consecutive cases," *International Journal of Periodontics and Restorative Dentistry*, vol. 31, no. 1, pp. 9–17, 2011.
- [5] J. A. Shibili, S. d'Avila, and E. Marcantonio Jr, "Connective tissue graft to correct peri-implant soft tissue margin: A clinical report," *Journal of Prosthetic Dentistry*, vol. 91, pp. 119–122, 2004.
- [6] P. Mercier and R. Lafontant, "Residual alveolar ridge atrophy: Classification and influence of facial morphology," *Journal of Prosthetic Dentistry*, vol. 41, no. 1, pp. 90–100, 1979.
- [7] Shibili JA et al. Regeneração tecidual: o que realmente sabemos?. São Paulo: VM Cultural, 2016.
- [8] J. Y. Oda and J. Carvalho, "Cicatrização do periodonto: revisão," *Arquivos de Ciências da Saúde UNIPAR*, vol. 8, no. 2, pp. 159–166, 2004.
- [9] A. G. Fardin, E. C. G. Jardim, F. C. Pereira, M. H. Guskuma, A. M. Aranega, and I. R. Garcia Junior,

- “Enxerto ósseo em odontologia: revisão de literatura, ”*Innovations Implant Journal*, vol. 5, no. 3, pp. 48–52, 2010.
- [10] Soares MVR. Biomateriais utilizados na prática odontológica: uma revisão de literatura. Trabalho de Conclusão de Curso. Londrina: Universidade Estadual de Londrina; 2015.
- [11] M. S. Block and M. Degen, “Horizontal ridge augmentation using human mineralized particulate bone: preliminary results, ”*Journal of Oral and Maxillofacial Surgery*, vol. 62, no. 9, pp. 67–72, 2004.
- [12] Misch C. Implantes dentais contemporâneos. 3. ed. Rio de Janeiro: Elsevier; 2008.
- [13] Hupp JR. Cirurgia oral e maxilofacial contemporânea. 5. ed. Rio de Janeiro: Elsevier; 2009.
- [14] S. Mouraret, E. Von Kaeppler, C. Bardet et al., “The potential for vertical bone regeneration via maxillary periosteal elevation, ”*Journal of Clinical Periodontology*, vol. 41, no. 12, pp. 1170–7, 2014.
- [15] H. S. Kim, Y. K. Kim, and P. Y. Yun, “Minimal invasive horizontal ridge augmentation using subperiosteal tunneling technique, ”*Maxillofacial Plastic and Reconstructive Surgery*, vol. 38, no. 1, pp. 41, 2016.
- [16] A. Kakar, K. Kakar, B. H. Sripathi Rao et al., “Lateral alveolar ridge augmentation procedure using subperiosteal tunneling technique: a pilot study, ”*Maxillofacial Plastic and Reconstructive Surgery*, vol. 40, no. 1, 2018.
- [17] J. Li, F. Xuan, B. H. Choi, and S. M. Jeong, “Minimally invasive ridge augmentation using xenogenous bone blocks in an atrophied posterior mandible: a clinical and histological study, ”*Implant Dentistry*, vol. 22, no. 2, pp. 112–116, 2013.
- [18] M. S. Block, “Closed approach for horizontal augmentation of the maxilla, ”*Journal of Oral and Maxillofacial Surgery*, vol. 76, no. 3, pp. 521–527, 2018.
- [19] H. Siadat, A. Rokn, and E. Beyabanaki, “Full arch all-on-4 fixed implant-supported prostheses with 8.5 years of follow-up: a case report, ”*Journal of Dentistry*, vol. 15, no. 4, pp. 259–265, 2018.
- [20] G. V. Da Silva Salomão, F. T. Santos, and S. Allegrini Junior, “The importance of prosthetic planning for implant-supported dentures in esthetic zones – A case report, ”*International Journal of Surgery Case Reports*, vol. 54, pp. 15–19, 2019.
- [21] A. P. Amoroso, H. Gennari Filho, E. P. Pellizzer, M. C. Goiato, J. F. Santiago Junior, and L. M. R. Villa, “Planejamento reverso em implantodontia: relato de caso clínico, ”*Revista Odontológica de Araçatuba*, vol. 33, no. 2, pp. 75–79, 2012.
- [22] R. S. Stein, “Estudo comparativo da neoformação óssea utilizando-se o enxerto ósseo autógeno e três substitutos – defeitos ósseos em ratos. Dissertação de mestrado, ”*Porto Alegre: Pontifícia Universidade Católica*, 2009.
- [23] J. W. Yang, H. J. Park, K. H. Yoo et al., “A comparison study between periosteum and resorbable collagen membrane on iliac block bone graft resorption in the rabbit calvarium, ”*Head & Face Medicine*, vol. 10, no. 15, 2014.
- [24] A. Bow, D. E. Anderson, and M. Dhar, “Commercially available bone graft substitutes: the impact of origin and processing on graft functionality, ”*Drug Metabolism Reviews*, vol. 51, no. 4, pp. 533–544, 2019.
- [25] Pimentel AC, Manzi MR, Kim YJ, Polo CI, Naclério-Homem MG. Utilização do enxerto homólogo na região posterior da mandíbula: relato de um caso. [publicação online];[acesso em 5 de dezembro de 2019]. Disponível em <https://www.fundect.com.br/pdf/artigograca.pdf>
- [26] A. Ivanov, T. I. Danilova, O. P. Popova, A. I. Erohin, and E. S. Semeniuhina, “Peculiarities of osteogenesis by periosteal cells after experimental ectopic transplantation, ”*Bulletin of Experimental Biology and Medicine*, 2018.
- [27] C. Colnot, X. Zhang, and M. L. Knothe Tate, “Current insights on the regenerative potential of the periosteum: molecular, cellular, and endogenous engineering approaches, ”*Journal of Orthopaedic Research*, vol. 30, no. 12, pp. 1869–78, 2012.
- [28] M. Takano, K. Sugahara, M. Koyachi et al., “Maxillary reconstruction using tunneling flap technique with 3D custom-made titanium mesh plate and particulate cancellous bone and marrow graft: a case report, ”*Maxillofacial Plastic and Reconstructive Surgery*, vol. 41, no. 1, pp. 43, 2019.
- [29] G. R. Deeb, G. H. Wilson, C. K. Carrico, U. Zafar, D. M. Laskin, and J. G. Deeb, “Is the tunnel technique more effective than open augmentation with a titanium-reinforced polytetrafluoroethylene membrane for horizontal ridge augmentation?”*Journal of Oral and Maxillofacial Surgery*, vol. 74, no. 9, pp. 1752–6, 2016.